

A novel method of Mohs defect closure using posterior deltoid skin

Nicole Vesely, BS,^a Steven Mark Burnett, MD,^b and J Morgan O'Donoghue, MD^c
Sarasota, Florida

Key words: Mohs micrographic surgery; posterior deltoid graft; skin graft.

SURGICAL CHALLENGE

Patients who undergo Mohs surgery may be left with sizeable defects and require skin grafts. Repair may prove especially challenging when the surgeon is faced with a large defect in a patient who is elderly with fragile, atrophic skin. Traditional donor sites for harvesting grafts can be difficult for patients to care for, heal slowly, and result in poor cosmesis.

SOLUTION

Mohs surgery of the lower tibia resulted in a 3 × 4-cm defect (Fig 1, A). A graft was determined to be the best closure option. The upper lateral arm was chosen as the donor site; this location provides an accessible area for the patient to care for and, when healed, often resembles the scar that commonly results from smallpox vaccinations (Fig 2).

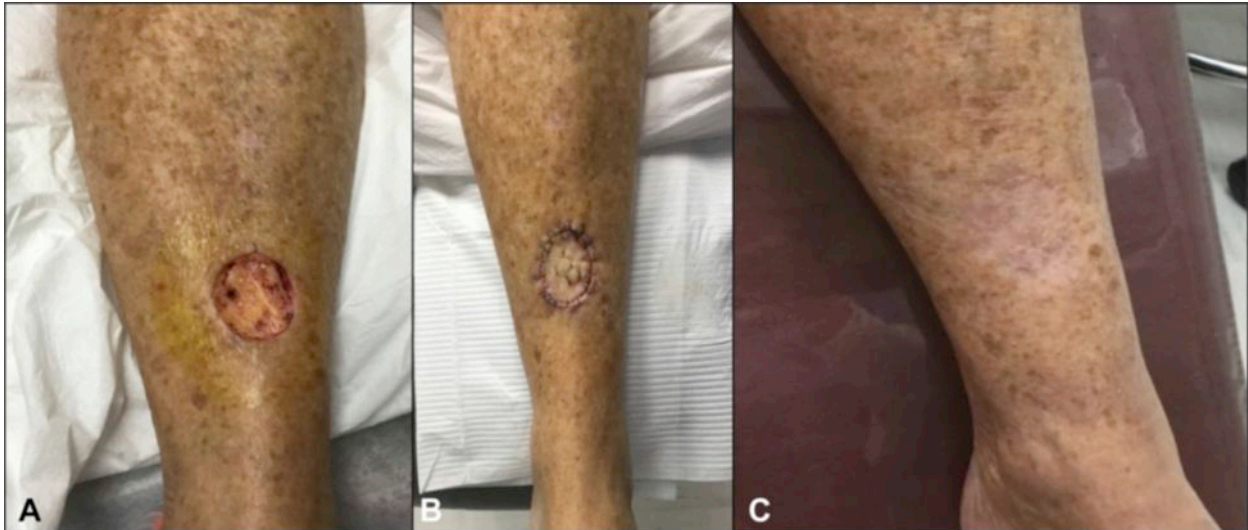


Fig 1. A, Lower tibial defect. B, Graft sutured in place. C, Healed lower tibial graft site.

From University of Florida College of Medicine,^a Sarasota, Florida,
Burnett Dermatology,^b Sarasota, Florida O'Donoghue Derma-
tology,^c Sarasota, Florida.

Funding sources: None.

Conflicts of interest: None disclosed.

Reprints not available from the authors.

Correspondence to: J Morgan O'Donoghue, MD, 1952 Field Rd,
Sarasota, FL 34231. E-mail: hoyaderm@gmail.com.

J Am Acad Dermatol 2019;■■■:e■■-■.

0190-9622/\$36.00

© 2019 by the American Academy of Dermatology, Inc.

<https://doi.org/10.1016/j.jaad.2019.09.076>

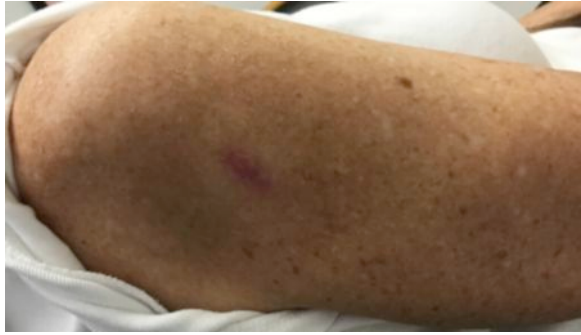

Fig 2. Healed posterior upper deltoid donor site.

The donor site on the upper deltoid is marked and anesthetized. A flexible disposable blade is coated with petrolatum, and graft excision is performed using delicate, side-to-side movements. The flexible blade allows precise control of the diameter, thickness, and beveled peripheral graft edge. The size of this donor tissue should be approximately 10% larger than the defect to account for normal tissue contraction. The graft is then gently trimmed and secured in the defect with interrupted 6.0 nylon sutures. Several 2-mm slits are placed in the graft to allow for exudative drainage, and a bolster is applied (Fig 1, B). This surgical technique illustrates the benefits of the posterior upper arm as a donor site, ease of use, quick healing, and excellent cosmesis (Fig 1, C).

We thank Dr S. Mark Burnett for sharing this interesting surgical technique.